

RESEARCH ARTICLE**Biologic Knee Arthroplasty in 360 Degrees for Early Osteoarthritis Treatment****Authors**

Alberto Gobbi MD

O.A.S.I. Bioresearch Foundation Gobbi N.P.O.

Via Amadeo 24, 20133 Milan, Italy

E-mail : agobbi@cartiagedoctor.it

*Macarena Morales MD

O.A.S.I. Bioresearch Foundation Gobbi N.P.O.

Via Amadeo 24, 20133 Milan, Italy

E-mail: dra.macarenamorales@hotmail.com

Giacomo Valsecchi

O.A.S.I. Bioresearch Foundation Gobbi N.P.O.

Via Amadeo 24, 20133 Milan, Italy

E-mail: fellow@oasiortopedia.it

Abstract

This article gives a comprehensive review of a two-step single surgical alternative that searches to preserve the patient's cartilage and joint. It addresses the knee from a 360-degree perspective; First, from the articular side, full-thickness cartilage lesions are treated with hyaluronic acid (HA) scaffold combined with bone marrow aspirate concentrate (BMC), which restores the articular cartilage with a hyaline-like tissue. Then, deep inside the subchondral bone, a minimally invasive procedure called Osteo-Core-Plasty (OCP) is conducted when it is affected. This procedure serves to restore the subchondral bone with structural bone autograft and BMAC derived signaling cells. The HA-BMC cartilage preserving technique with more than ten years of follow-up provides persistent and prosthesis sparing surgical results, while OCP offers the further benefits of the new technology for deep joint bone-core treatment and regeneration with significant improvement in clinical score outcomes and magnetic resonance imaging. Given the evidence, these articular preservation techniques can be considered the new paradigm knee arthroplasty surgery as they can achieve a valuable and holistic approach to early osteoarthritis treatment.

Keywords: stem cells, scaffold, osteoarthritis, hyaluronic acid, cartilage regeneration, subchondral bone, bio-orthopaedics

1. Introduction:

Osteoarthritis (OA) is one of the most prevalent degenerative joint diseases; the aggregated global prevalence of knee OA can be as high as 16% (95% CI, 14,3%-17,8%) in individuals more than 15 years old and 22,9% (95%CI, 19,8%-26,1%) in individuals aged 40 and over, with a peak prevalence at 70-79 years old¹. Its main characteristic is the generation of significant joint pain and functional impairment, accounting for the 15th highest cause of years lived with disability worldwide². OA is a multifactorial disease that depends on individual factors like gender, genetic inheritance (3), and acquired factors like high-impact sports or previous knee injury^{3,4}. In addition, it has increasingly been correlated with patients' metabolic conditions, including visceral obesity, insulin resistance, low-HDL cholesterol, and high triglycerides⁵. The exponential increase of OA makes this disease a major social problem, which nowadays, with better diagnostic technologies and a better understanding of OA pathogenesis, makes it imperative to search for long term reproducible and accessible solutions for cartilage injury with its primary focus on disease prevention and early treatment rather than end-stage disease solutions like total knee arthroplasty (TKA). This article describes two minimally invasive joint preserving surgical techniques for early osteoarthritis, HA-BMAC scaffold for articular cartilage lesions and Osteo-Core-Plasty for subchondral bone treatment.

2. One-step treatment for chondral lesion HA-BMAC

2.1. Articular cartilage

Joints are lined with smooth articular cartilage essential for low friction movement and optimal shock absorption⁵. Chondral lesions occur mainly in the medial

femoral condyle, which is related to the direct loading stress that receives, and almost 60% of the incidence has been reported in patients between 40 and 50 years of age; a significant percentage population which may not be yet suitable for arthroplasty^{8,9}. It is well known that cartilage has poor repair capacity, and if left untreated, the defect will continue to progress, exposing the underlying bone, leading to damage of subchondral bone and finally producing early OA^{9,10}. Cartilage repair treatments were developed with their primary focus set on regeneration and replacement of the hyaline cartilage rather than compromising the articulation with TKA. Over the years, several techniques in cartilage restoration have been developed. Autologous chondrocyte implantation (ACI) was one of the first techniques shown to stimulate the production of hyaline-like repair tissue, providing a stable clinical improvement^{11,12}. The evolution of this technique led to the development of scaffolds that allowed cell ingrowth but did not eliminate the need for the second-stage chondrocyte harvest and cultivation. For this purpose, a one-step procedure was created that led to BMAC use, which contains multipotent stem cells (MSC) and growth factors with a hyaluronan-based scaffold to treat chondral injuries.

2.2. Hyaluronan-based scaffold

Tissue engineering aims to use biodegradable polymers as temporary scaffolds for the in vitro growth of cells¹³; these must be biocompatible and promote chondrocyte attachment and proliferation¹⁴. Hyaluronic acid is a naturally occurring glycosaminoglycan that has proven to be an ideal molecule for tissue engineering in cartilage repair¹⁴. Through chemical modifications, it may be processed into stable configurations to produce

biodegradable structures with different physical forms and in-vivo residence times (Fig.1) ¹⁴. Furthermore, extensive biocompatibility studies have demonstrated their safety and ability to be reabsorbed without an inflammatory response ^{15,16}. For

this reason, a three-dimensional non-woven HA scaffold is used in the described cartilage repair technique to support in vitro chondrocytes growth and help promote the expression of their original chondrogenic phenotype ¹⁵.




Figure 1: Hyaluronic-Based Scaffold

2.3. Bone marrow aspirate concentrate

BMC consists of bone marrow stem cells (BMSC), platelets containing growth factors, and hematopoietic cells facilitating osteochondral healing^{17,18}. Under static culture conditions, BMSC have been shown to interact with the non-woven hyaluronic acid scaffold, providing cellular migration, adhesion, and proliferation^{19,20}. Several studies support the HA-BMAC combination as a valuable tool for treating full-thickness cartilage lesions of the knee²¹⁻²⁴. Nejadnik et al. compared the clinical outcomes of patients treated with first-generation autologous chondrocyte implantation (ACI) and patients treated with autologous BMSC and concluded that BMSC are as effective as chondrocytes for articular cartilage repair²⁵. In another study, patients treated with matrix-induced autologous chondrocyte implantation (MACI) were

compared with patients treated with BMSC combined with HA scaffold; at three years follow up, there were no significant statistical differences between the two groups, concluding that both of these techniques are viable and effective²⁶, with the difference that HA-BMAC surgical technique can be performed in just one surgery without the need of further cell cultivation or amplification.

2.4. Surgical Technique

The procedure is performed under general anesthesia. Before the intervention begins, the injured knee is examined to recognize other possible concomitant pathologies like instability. Afterward, the ipsilateral iliac crest is exposed for bone marrow aspiration. Cartilage lesions are identified during diagnostic arthroscopy. Arthroscopic intervention is only possible if the lesion can

be fully visualized with the arthroscope and reached with the chondrectomes; if not, an arthrotomy is performed. First, thorough debridement of the loose chondral tissue is necessary, ensuring that the lesion's borders are vertical to the subchondral plane (Fig.2). The calcified cartilage layer overlying the subchondral bone is removed, preserving the subchondral plate. The lesion dimensions are measured to prepare the matching implant using the three-dimensional HA scaffold. BMAC can be activated with the batroxobin enzyme to form a sticky clot (Fig 3), facilitating easier application (Fig.4). Finally, the HA-BMAC is implanted into the lesion (Fig. 5). A crucial part of the procedure is to check the implant stability; for this purpose, the joint

is manipulated through a range of motion several times while the scaffold is observed via arthroscopy. Fibrin glue can be applied to improve implant stability^{23,24,27}.

In cases where osteochondral lesions are evident, a malleable bone graft inlay can be constructed with morselized bone autologous cancellous graft rich in mesenchymal stem cells collected simultaneously from bone marrow aspiration site. This technique was described by Sadlik et al.²⁸ and is referred to as Biologic Inlay Osteochondral Reconstruction (BIOR). This single-stage reconstruction procedure's versatility makes it an interesting off-shelf surgical treatment method, given the cost-effective nature and technical versatility of the technique.

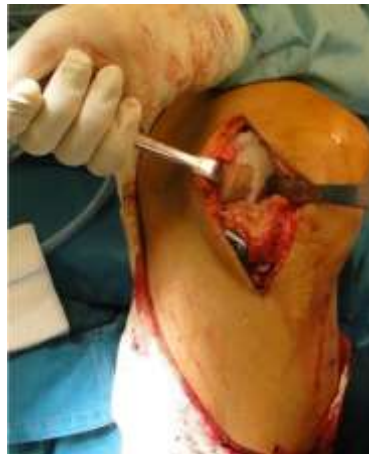

Figure 2. Intraoperative image: Prepared cartilage defect in the medial femoral condyle



Figure 3. Intraoperative image: Activated BMAC




Figure 4. Intraoperative image: A) BMAC extraction from iliac crest. B) Sized hyaluronic-acid scaffold. C) HA Scaffold seeded with BMC

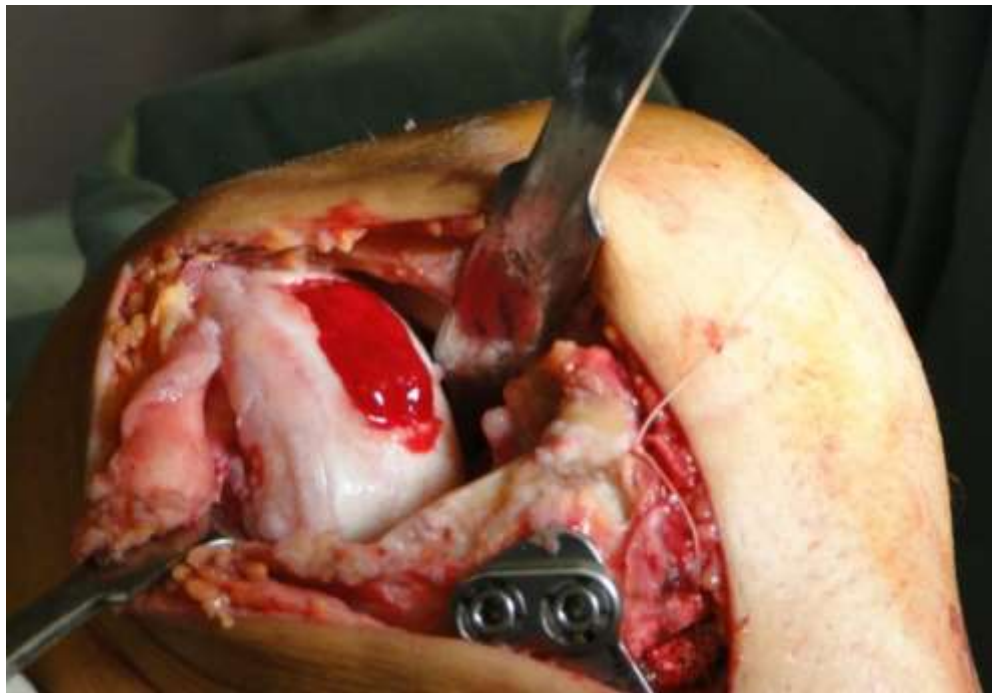

Figure 5. Intraoperative image: HA-BMAC implanted into the cartilage defect.

3.5.1 Clinical Outcomes

HA- BMAC surgical technique for full-thickness chondral lesion treatment has ten years of good to excellent outcomes. A group of twenty-three physically active patients with a mean age of 48.5 years treated with HA-BMAC technique were followed prospectively. Chondral defect size was at least one cm² and classified as grade IV according to International Cartilage Repair Society (ICRS) criteria.

The defect could be localized in the patella, trochlea, or femoral condyle. Magnetic resonance imaging was used for diagnostic and pre-operative assessment of cartilage lesions. For outcome measure, patient-reported assessment Tegner Activity Scale, visual analog scale (VAS), International Knee Documentation Committee (IKDC) subjective score, and Knee injury and Osteoarthritis Outcome Score (KOOS) were used preoperatively, at short-term follow-up

(2 years), and long-term follow-up. At the final follow-up, all scores were significantly increased ($P < 0.001$). Median cartilage lesion size was 6.5 cm² (range, 2 to 27 cm²), and a negative correlation was found between patient age and final outcome scores of; IKDC, Tegner, and KOOS.²¹⁻²⁴ Results also demonstrated that different-sized osteochondral lesions could be addressed with this technique, from minor-sized lesions to significant defects up to 22 cm² showing good clinical outcomes at long-term follow-up²¹⁻²⁴. Interestingly, when one compares bone marrow stimulating procedures such as microfracture, the HA-BMAC technique has proven effective in treating patients over 45 years of age^{27,29,30}. In conclusion, cell-based cartilage repair performed in a single stage with an HA scaffold associated with BMAC has demonstrated successful long-term clinical outcomes, comparable with outcomes expected from 2-stage procedures²¹⁻²⁴. Nevertheless, is essential to recall that to obtain the desired results, the knee joint should to be considered in its entirety, and other lesions such as meniscal tears, knee malalignment, instability, or even metabolic diseases have to be treated to achieve an optimal result.

3. One-step treatment for subchondral bone Osteo-Core-Plasty

3.1. Subchondral bone:

Subchondral bone is essential for optimal cartilage functioning. Its trabecular component provides elasticity and shock absorption during weight-bearing, and its compact subchondral bone plate provides firm support for cartilage³¹. Moreover, it is designed to dissipate the axial load across the joint, sparing the overlying articular cartilage³². Another essential function of subchondral bone is to provide blood supply to cartilage, as it possesses an essential arteriovenous complex that penetrates the

subchondral bone plate and reaches the calcified cartilage layer³⁴. These vascular perforations were shown to be present at a higher degree in weight loading areas, which coincide with areas of greater bone remodeling³⁵, supporting the critical role that vascularity has in the natural healing processes.

When subchondral bone is damaged, it releases inflammatory mediators that can eventually degrade the deeper layers of articular cartilage³⁶. Changes observed on the microarchitectural level correspond to coalescing microfractures seen in Magnetic Resonance Imaging (MRI) as bone marrow edema lesions (Fig. 6). Furthermore, the increasing rate of new bone formation reduces the size of bone marrow spaces, potentially resulting in an ischemic state, with decreased healing capacity due to poor tissue nutrition³⁷. If the inflammatory process continues, its mechanical properties become permanently altered, conducting to a sclerotic bone with reduced shock-absorbing capability and increased risk of shear-induced tensile failure of articular cartilage³⁸.

For this reason, the goal for subchondral bone treatment includes decreasing the progression of the disease through pain relief and restoration of bone architecture. Bone marrow adjuncts to address subchondral lesions have been widely researched as they have proven to have a beneficial effect in improving function; Hernigou et al., in an RCT in 120 knees, compared subchondral bone infiltrations with intra-articular injection of bone marrow concentrate mesenchymal stem cells in bilateral knee osteoarthritis³⁹; They concluded that implantation of MSCs in the subchondral bone was more effective in preventing TKA than the intra-articular injection of the same dose in the contralateral knee with the same osteoarthritis grade. In a pilot study of a

combined subchondral and intraarticular BMAC injective treatment, Kon et al. showed overall positive outcome results and safety in treating patients with symptomatic

knee OA associated with subchondral bone alterations; as they showed to progress with a reduction of bone marrow edema at 12 months follow-up⁴⁰.

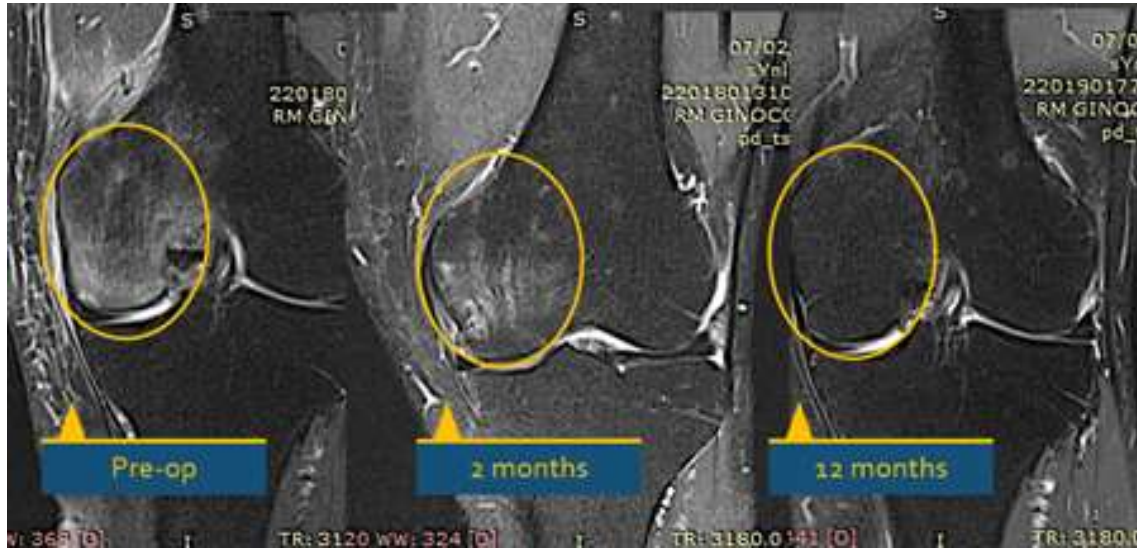


Figure 6. MRI follow-up images after Osteo-Core-Plasty. It shows the gradual decrease of bone marrow edema: previous to operation, at two months and 12 months.

3.2. Surgical Procedure

The Marrow Cellution System consisting of an advanced method to collect high quality bone marrow aspirate (BMA) and intact cancellous bone dowels creates the opportunity to address subchondral lesions in an innovative minimally invasive treatment called “Osteo-Core-Plasty”. The procedure facilitates: A) Bone marrow decompression to decrease intraosseous pressure and necrotic bone resection. B) Minimally invasive BMAC administration to improve biological healing potential and C) Structural support with bone autograft (bone dowels) with osteoconductive, osteoinductive, and osteogenic capacity components to provide an optimized environment for subchondral bone regeneration.

3.2.1. Osteo-Core-Plasty: Initial Phase

The procedure's initial phase is to obtain the autologous bone marrow aspirate samples

for biological healing stimulation and cancellous bone graft for structural support (Marrow Cellution, Aspire Medical Innovation, Germany)⁴¹. The patient, under regional or spinal anesthesia, is placed in a supine position as used in standard knee arthroscopy. A bone marrow aspiration needle is inserted into the cortex of the iliac crest; once the needle passes through the cortex, the sharp stylet is exchanged for a blunt stylet that is manually advanced into the medullary canal. The blunt stylet is then replaced with a fenestrated aspiration cannula (Fig.7). The difference of this system with standard marrow aspiration is that the aspirate flow is collected exclusively laterally as the tip of the aspiration cannula is closed, allowing marrow collection perpendicular to and around the channel created by the device's tip (Fig.8). This allows the extraction of multiple small volumes of high-quality bone marrow aspirate collected from various sites

distributed within the marrow cavity. Finally, a special trephine needle is used for bone dowel harvest depending on the severity and the size of the lesion to be treated. (Fig. 9)

A single puncture with this technique is functionally equivalent to repeated puncture sites with a traditional trocar needle collecting small aspirate volumes, but with substantial savings of time, effort, patient trauma, and risk of infection. The background of this benefit is supported in a recent study by Everts et al., in which the count of colony-forming units (CFU) was significantly increased only in the first 10 ml of BMAC⁴². Hernigou et al. supported the results obtained in this study, showing that large volume aspirates tend to be infiltrated by significant amounts of

peripheral blood, containing fewer MSCs, leading to lower CFU/f counts⁴³. This approach also overcomes the requirement of additional manipulation techniques i.e. centrifugation. It has been shown that Marrow Cellution contains a higher quantity of specific cell markers such as; CD73+, CD105+, CD117+ (c-Kit); five times more than crest aspirate, and tenfold more than tibia aspirate⁴⁴. Other studies have also supported these findings, for example, in a side-by-side comparison from the same patients using the contralateral iliac crest, the level of CFU-fs/mL was significantly higher in the Osteo-Core-Plasty compared to BMCs⁴⁵ and showed the same numbers of CD34+ and CD117+ cells compared to centrifugation techniques⁴⁵




Figure 7 Osteo-Core-Plasty (Marrow Cellution). Instruments included; Sharp stylet, blunt stylet, and fenestrated aspiration cannula.

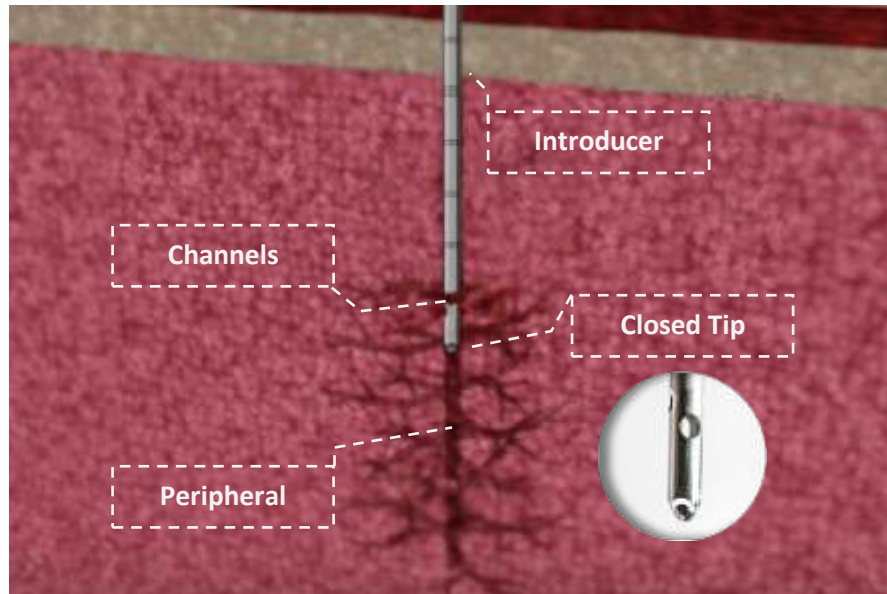


Figure 8. Osteo-Core-Plasty™. Functional design of the Marrow Cellution™ System includes two unique features: Closed needle tip to prevent aspiration of excess blood from the entry channel and a handle with a threaded guide.

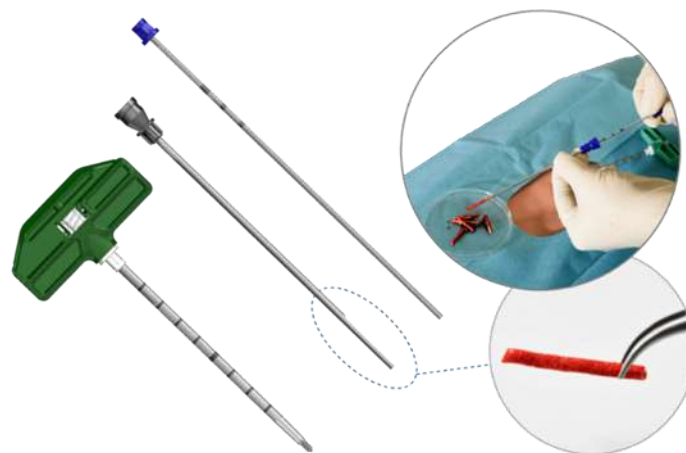


Figure 9. Osteo-Core-Plasty™: The MC-RAN-8C Marrow Cellution™ System provides the additional benefit to percutaneously harvest autologous bone graft in the same minimally invasive procedure.

3.2.2. Osteo-Core-Plasty: Second phase

The second phase of the procedure is the delivery of intact autogenous cancellous dowels and bone marrow aspirate to the subchondral lesion site. Anteroposterior and lateral fluoroscopic images cross-referenced with the MRI study are used to place the guide pin precisely in the subchondral defect (Fig.10-11), a cannulated drill is

inserted over the guide pin and its left for a few minutes in the bone to perform core decompression (Fig. 12). K-Wire and necrotic bone core are then removed. Extraction/Delivery Tool containing Marrow Cellution™ bone core graft is then inserted (Fig 13-15). A probe is used to push the bone core graft to the distal position. Then, the Marrow Cellution™ Liquid is

injected (Fig. 16) ⁴¹. A final arthroscopic look is performed to confirm the lack of intra-articular leakage.

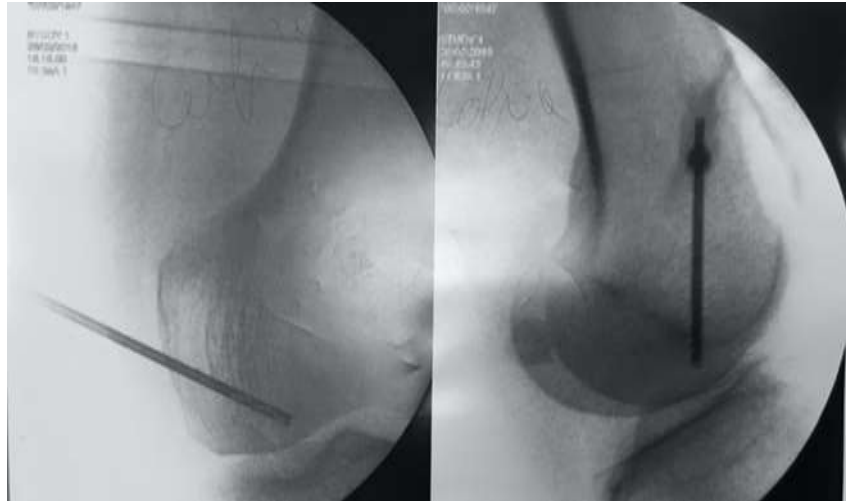


Figure 10. The procedure performed under radioscopic guidance. Images in correspond to Fig 6 MRI, medial femoral condyle subchondral lesion.

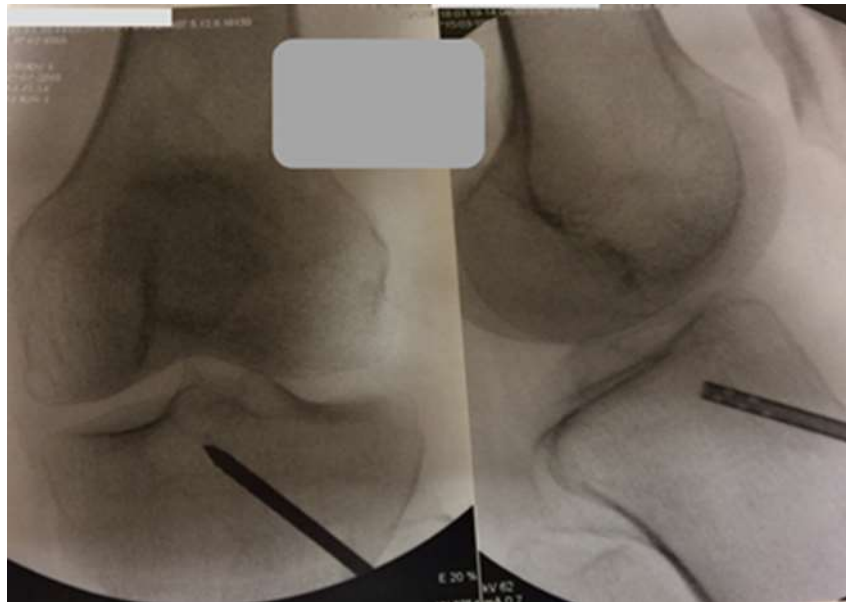

Figure 11. Osteo-Core-Plasty. Radioscopic guided pin placement over a tibial subchondral cyst.

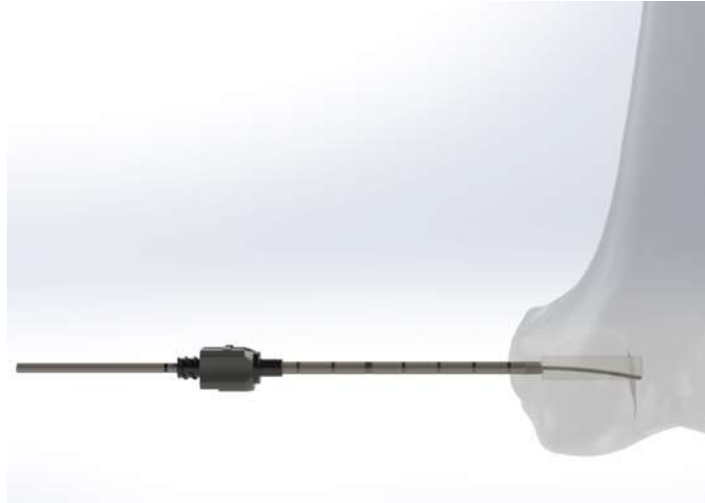


Figure 12. Osteo-Core-Plasty: Representation of minimally invasive core decompression and debridement of the subchondral lesion.

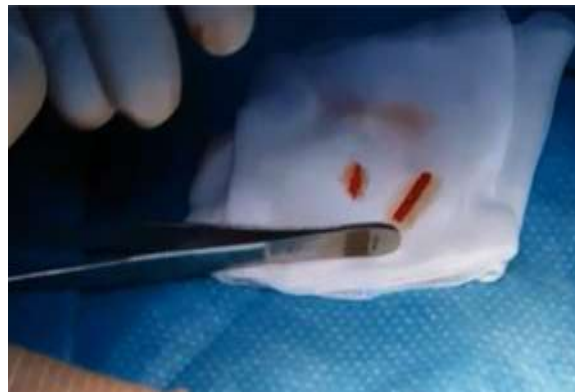

Figure 13. Osteo-Core-Plasty: Intact bone dowels

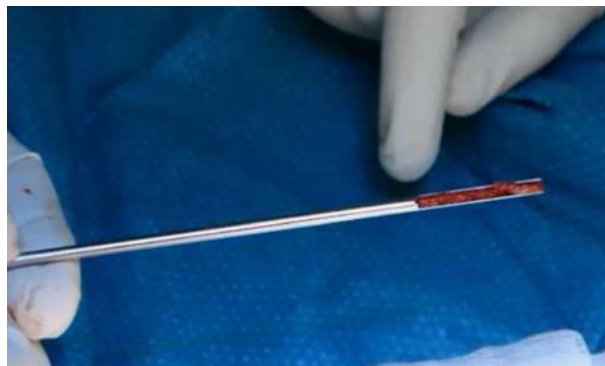


Figure 14. Osteo-Core-Plasty: Extraction/Delivery tool containing bone core graft.




Figure 15. *Osteo-Core-Plasty: Extraction/Delivery tool with bone core graft application into the defect.*

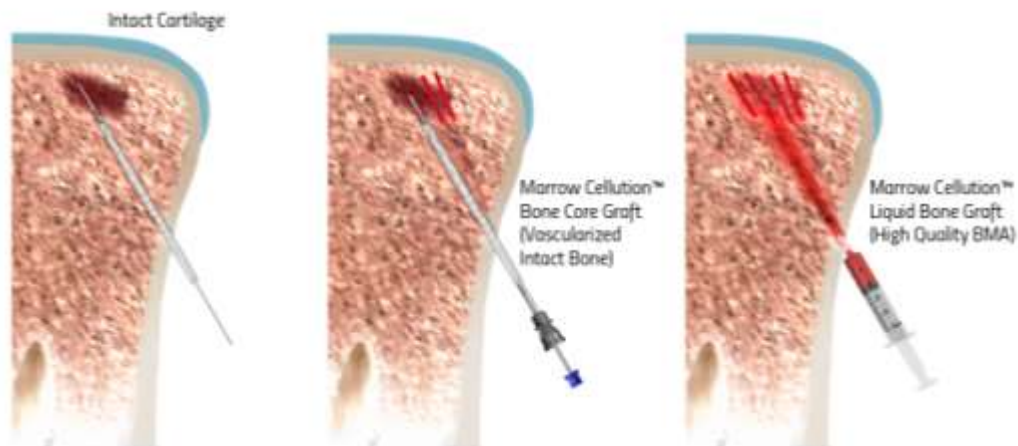


Figure 16. *Osteo-Core-Plasty™. Procedure representation Intact cartilage subchondral lesion. A) Decompression. B) Bone core autograft administration. C) BMC Marrow Cellulation injection* ⁴⁶.

3.3. Clinical Outcomes

Fifteen patients with symptomatic Bone Marrow Lesions (BML) of the knee treated with the Osteo-Core-Plasty technique were included and followed prospectively for a minimum of 12 months. Inclusion criteria were carefully selected patients, with symptomatic bone marrow lesions, with OA, grade I-II, no malalignment that did not respond to conservative treatment for more than three months. Exclusion criteria were poor subchondral bone quality, instability, severe osteoarthritis, osteonecrosis with collapse. Each patient was evaluated before the surgery and respectively at 6 and 12

months using the scores of Tegner, Marx, IKDC, KOOS and VAS. All of the clinical scores except Tegner and Marx score showed an overall statistically significant improvement through the entire follow-up ($p < 0.05$) and a significant improvement ($p < 0.05$) between each follow-up period (T_0 versus T_1 ; T_0 versus T_2 ; T_1 versus T_2). No complications were reported. These preliminary results confirm that biological subchondral bone augmentation by Osteo-Core-Plasty technique is a safe and effective minimally invasive treatment option for symptomatic BML in the knee at 1-year follow-up (Fig.17).

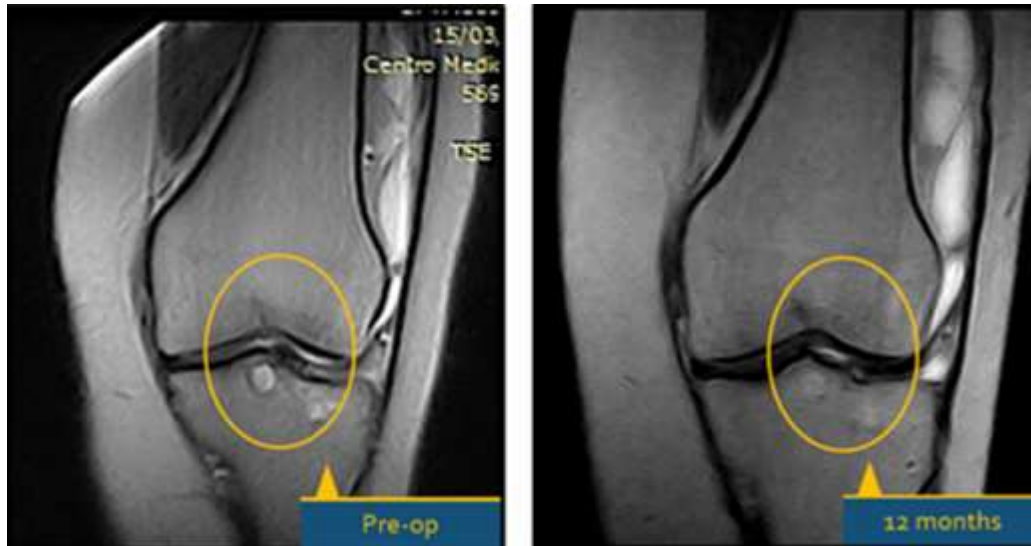


Figure 17. Osteo-Core-Plasty. M.R.I. of a tibial cyst treated with OCP, at 12 months follow-up. Images in correspondence with X-Rays in figure 11.

Table 1. Benefits of Marrow Cellution

Maximizes Cell Yield
Minimally Invasive
Centrifugation not Required
Never Leaves the Sterile Field
Reduces Blood Contamination
Regulatory Compliant
Reduces Donor Site Morbidity
It does not Burn any Bridge

4. Conclusions

Cartilage and subchondral bone work in synchronization; therefore, it is crucial to address both of them to achieve optimal results. For this purpose, joint preserving prosthesis sparing surgical techniques such as HA-BMAC for cartilage lesions and Osteo-Core-Plasty for subchondral bone defects have been developed. Both are single-step osteochondral repair treatments that eliminate the need for a two-step procedure, thereby reducing the cost and morbidity to the patient. In addition, HA-

BMAC is a safe and accessible procedure that provides excellent clinical outcomes at long-term follow-up in small or large lesions, single or multiple injuries, and in various compartments; Osteo-Core-Plasty, on the other hand, is a new minimally invasive procedure with reported efficacy in treating painful subchondral bone lesions. Given the evidence and versatility of this treatment approach, it may become essential in early osteoarthritis cartilage treatments and should be seriously considered in younger, active patients who wish to reduce pain.

Bibliography

1. Cui A, Li H, Wang D, Zhong J, Chen Y, Lu H. Global, regional prevalence, incidence and risk factors of knee osteoarthritis in population-based studies. *EClinicalMedicine*. 2020;29-30.
doi:10.1016/J.ECLINM.2020.100587/ATTACHMENT/F3A46851-2688-43C2-A7F4-563FCF81D41F/MMC30.DOCX
2. Global Burden of Disease Collaborative Network. Global Burden of Disease Study 2019 (G.B.D. 2019) results. 2020. <http://ghdx.healthdata.org/gbd-results-tool> (accessed Ago 8, 2020). Accessed August 10, 2021. <http://ghdx.healthdata.org/gbd-results-tool>
3. Silverwood V, Blagojevic-Bucknall M, Jinks C, Jordan JL, Protheroe J, Jordan KP. Current evidence on risk factors for knee osteoarthritis in older adults: a systematic review and meta-analysis. *Osteoarthr Cartil*. 2015;23(4):507-515.
doi:10.1016/J.JOCA.2014.11.019
4. Vigdorichik JM, Nepple JJ, Eftekhary N, Leunig M, Clohisy JC. What Is the Association of Elite Sporting Activities With the Development of Hip Osteoarthritis?: <https://doi.org/10.1177/0363546516656359>. 2016;45(4):961-964.
doi:10.1177/0363546516656359
5. Gobbi A, Lane J, Giuseppe L, Dallo I. *Joint Function Preservation; A Focus on the Osteochondral Unit*. SPRINGER NATURE; 2021.
6. Bierma-Zeinstra SMA, Waarsing JH. The role of atherosclerosis in osteoarthritis. *Best Pract Res Clin Rheumatol*. 2017;31(5):613-633.
doi:10.1016/J.BERH.2018.08.006
7. Hall AJ, Stubbs B, Mamas MA, Myint PK, Smith TO. Association between osteoarthritis and cardiovascular disease: Systematic review and meta-analysis. *Eur J Prev Cardiol*. 2016;23(9):938-946.
doi:10.1177/2047487315610663
8. Widuchowski W, Widuchowski J, Trzaska T. Articular cartilage defects: Study of 25,124 knee arthroscopies. *Knee*. 2007;14(3):177-182.
doi:10.1016/j.knee.2007.02.001
9. Flanigan DC, Harris JD, Trinh TQ, Siston RA, Brophy RH. Prevalence of chondral defects in Athletes' Knees: A systematic review. *Med Sci Sports Exerc*. 2010;42(10):1795-1801.
doi:10.1249/MSS.0b013e3181d9eea0
10. Hunter W. Of the structure and disease of articulating cartilages. 1743. *Clin Orthop Relat Res*. 1995;(317):3-6. Accessed January 19, 2022.
<https://pubmed.ncbi.nlm.nih.gov/7671493/>
11. Gobbi A, Lane JG, Dallo I. Editorial Commentary: Cartilage Restoration—What Is Currently Available? *Arthrosc - J Arthrosc Relat Surg*. 2020;36(6):1625-1628.
doi:10.1016/j.arthro.2020.04.001
12. Kon E, Filardo G, Gobbi A, et al. Long-term Results after Hyaluronan-based M.A.C.T. for the Treatment of Cartilage Lesions of the Patellofemoral Joint. *Am J Sports Med*. 2016;44(3):602-608.
doi:10.1177/0363546515620194
13. Tuli R, Li WJ, Tuan RS. Current state of cartilage tissue engineering. *Arthritis Res Ther*. 2003;5(5):235.
doi:10.1186/AR991
14. Dovedytis M, Liu ZJ, Bartlett S. Hyaluronic acid and its biomedical applications: A review. *Eng Regen*. 2020;1:102-113.

- doi:10.1016/J.ENGREG.2020.10.001
15. Grigolo B, Lisignoli G, Piacentini A, et al. Evidence for redifferentiation of human chondrocytes grown on a hyaluronan-based biomaterial (HYAFF®11): Molecular, immunohistochemical and ultrastructural analysis. *Biomaterials*. 2002;23(4):1187-1195. doi:10.1016/S0142-9612(01)00236-8
 16. Gobbi A, Whyte GP. Long-term clinical outcomes of one-stage cartilage repair in the knee with hyaluronic acid-based scaffold embedded with mesenchymal stem cells sourced from bone marrow aspirate concentrate. *Am J Sport Med*. 2019;47:1621-1628.
 17. Caplan AI. Review: mesenchymal stem cells: cell-based reconstructive therapy in orthopedics. *Tissue Eng*. 2005;11(7-8):1198-1211. doi:10.1089/TEN.2005.11.1198
 18. Hellingman CA, Davidson E.N.B., Koevoet W, et al. Smad signaling determines chondrogenic differentiation of bone-marrow-derived mesenchymal stem cells: Inhibition of Smad1/5/8P prevents terminal differentiation and calcification. *Tissue Eng - Part A*. 2011;17(7-8):1157-1167. doi:10.1089/ten.tea.2010.0043
 19. Pasquinelli G, Orrico C, Foroni L, et al. Mesenchymal stem cell interaction with a non-woven hyaluronan-based scaffold suitable for tissue repair. *J Anat*. 2008;213(5):520. doi:10.1111/J.1469-7580.2008.00974.X
 20. Lisignoli G, Cristino S, Piacentini A, et al. Chondrogenic differentiation of murine and human mesenchymal stromal cells in a hyaluronic acid scaffold: Differences in gene expression and cell morphology. *J Biomed Mater Res - Part A*. 2006;77(3):497-506. doi:10.1002/jbm.a.30632
 21. Gobbi A, Karnatzikos G, Petrera M. Biologic Arthroplasty for Full-thickness Cartilage Lesions of the Knee: Results at Three Years Follow-up (SS-56). *Arthrosc J Arthrosc Relat Surg*. 2013;29(6):e27. doi:10.1016/J.ARTHRO.2013.03.063
 22. Gobbi A, Karnatzikos G, Scotti C, Mahajan V, Mazzucco L, Grigolo B. One-step cartilage repair with bone marrow aspirate concentrated cells and collagen matrix in full-thickness knee cartilage lesions: results at 2-year follow-up. *Cartilage*. 2011;2(3):286-299. doi:10.1177/1947603510392023
 23. Gobbi A, Whyte G.P.G.P. Long-term Clinical Outcomes of One-Stage Cartilage Repair in the Knee With Hyaluronic Acid-Based Scaffold Embedded With Mesenchymal Stem Cells Sourced From Bone Marrow Aspirate Concentrate. *Am J Sports Med*. 2019;47(7):1621-1628. doi:10.1177/0363546519845362
 24. Whyte GP, Gobbi A, Sadlik B. Dry Arthroscopic Single-Stage Cartilage Repair of the Knee Using a Hyaluronic Acid-Based Scaffold With Activated Bone Marrow-Derived Mesenchymal Stem Cells. *Arthrosc Tech*. 2016;5(4):e913-e918. doi:10.1016/J.EATS.2016.04.020
 25. Nejadnik H, Hui JH, Choong EPF, Tai BC, Eng Hin Lee. Autologous bone marrow-derived mesenchymal stem cells versus autologous chondrocyte implantation: an observational cohort study. *Am J Sports Med*. 2010;38(6):1110-1116. doi:10.1177/0363546509359067
 26. Gobbi A, Chaurasia S, Karnatzikos G, Nakamura N. Matrix-Induced

- Autologous Chondrocyte Implantation versus Multipotent Stem Cells for the Treatment of Large Patellofemoral Chondral Lesions: A Nonrandomized Prospective Trial. *Cartilage*. 2015;6(2):82-97. doi:10.1177/1947603514563597
27. Gobbi A, Scotti C, Karnatzikos G, Mudhigere A, Castro M, Peretti GMGM. One-step surgery with multipotent stem cells and Hyaluronan-based scaffold for the treatment of full-thickness chondral defects of the knee in patients older than 45 years. *Knee Surgery, Sport Traumatol Arthrosc*. 2017;25(8):2494-2501. doi:10.1007/s00167-016-3984-6
 28. Sadlik B, Gobbi A, Puszczkarz M, Klon W, Whyte GP. Biologic Inlay Osteochondral Reconstruction: Arthroscopic One-Step Osteochondral Lesion Repair in the Knee Using Morselized Bone Grafting and Hyaluronic Acid-Based Scaffold Embedded With Bone Marrow Aspirate Concentrate. *Arthrosc Tech*. 2017;6(2):e383-e389. doi:10.1016/J.EATS.2016.10.023
 29. Gobbi A, Karnatzikos G, Lad D, Chaurasia S. Long-term Results after Microfracture Treatment of Full-thickness Knee Chondral Lesions in Athletes. *Arthroscopy*. 2014;30(6):e33. doi:10.1016/J.ARTHRO.2014.04.072
 30. Gobbi A, Whyte G.P.G.P. One-Stage Cartilage Repair Using a Hyaluronic Acid-Based Scaffold with Activated Bone Marrow-Derived Mesenchymal Stem Cells Compared with Microfracture. *Am J Sports Med*. 2016;44(11):2846-2854. doi:10.1177/0363546516656179
 31. Clark JM, Huber JD. The structure of the human subchondral plate. *J Bone Joint Surg Br*. 1990;72(5):866-873. doi:10.1302/0301-620X.72B5.2211774
 32. Radin EL, Paul IL. Response of joints to impact loading. I. In vitro wear. *Arthritis Rheum*. 1971;14(3):356-362. doi:10.1002/ART.1780140306
 33. McCarty D, a WK-A and allied conditions:, 1993 undefined. *Arthritis and allied conditions: a textbook of rheumatology*. *pesquisa.bvsalud.org*. Accessed January 12, 2022. <https://pesquisa.bvsalud.org/portal/resource/pt/biblio-971453>
 34. Imhof H, Breitensteher M, Kainberger F, Rand T, Trattnig S. Importance of subchondral bone to articular cartilage in health and disease. *Top Magn Reson Imaging*. 1999;10(3):180-192. doi:10.1097/00002142-199906000-00002
 35. L.B. L, A V, P.G. B, Lane LB, Villacin A, Bullough PG. The vascularity and remodelling of subchondrial bone and calcified cartilage in adult human femoral and humeral heads. An age- and stress-related phenomenon. *J Bone Joint Surg Br*. 1977;59(3):272-278. doi:10.1302/0301-620X.59B3.893504
 36. Berenbaum F. Osteoarthritis as an inflammatory disease (osteoarthritis is not osteoarthrosis!). *Osteoarthr Cartil*. 2013;21(1):16-21. doi:10.1016/J.JOCA.2012.11.012
 37. McIlwraith C, Frisbie D, Kawcak C, Weeren R Van. Joint disease in the horse. Published online 2015. Accessed January 12, 2022. https://books.google.com/books?hl=it&lr=&id=8LNgcGAAQBAJ&oi=fnd&pg=PP1&ots=WP_ob5QbRv&sig=aZMABdgIhJLog-Ml6cZTYt_zEdM
 38. Radin EL, Rose RM. Role of subchondral bone in the initiation and

- progression of cartilage damage. *Clin Orthop Relat Res.* 1986;213(213):34-40. doi:10.1097/00003086-198612000-00005
39. Hernigou P, Bouthors C, Bastard C, Flouzat Lachaniette CH, Rouard H, Dubory A. Subchondral bone or intra-articular injection of bone marrow concentrate mesenchymal stem cells in bilateral knee osteoarthritis: what better postpone knee arthroplasty at fifteen years? A randomized study. *Int Orthop.* 2021;45(2):391-399. doi:10.1007/S00264-020-04687-7
 40. Kon E, Boffa A, Andriolo L, et al. Subchondral and intra-articular injections of bone marrow concentrate are a safe and effective treatment for knee osteoarthritis: a prospective, multi-center pilot study. *Knee Surg Sports Traumatol Arthrosc.* 2021;29(12):4232-4240. doi:10.1007/S00167-021-06530-X
 41. Szwedowski D, Dallo I, Irlandini E, Gobbi A. Osteo-core Plasty: A Minimally Invasive Approach for Subchondral Bone Marrow Lesions of the Knee. *Arthrosc Tech.* 2020;9(11). doi:10.1016/J.EATS.2020.07.023
 42. Everts PA. Journal of Stem Cell Biology and Transplantation A comparative quantification in cellularity of bone marrow aspirated with two new harvesting devices, and the nonequivalent difference between a centrifugated bone marrow concentrate and a bone marrow aspirate as biological injectates, using a bi-lateral patient model. *J Stem Cell Biol Transpl 2020 Stem Cell Res.* Published online 2020.
 43. Hernigou P, Homma Y, Flouzat Lachaniette CH, et al. Benefits of small volume and small syringe for bone marrow aspirations of mesenchymal stem cells. *Int Orthop.* 2013;37(11):2279. doi:10.1007/S00264-013-2017-Z
 44. Viganò M, Ragni E, Di Matteo B, et al. A single step, centrifuge-free method to harvest bone marrow highly concentrated in mesenchymal stem cells: results of a pilot trial. *Int Orthop.* Published online 2021. doi:10.1007/s00264-021-05243-7
 45. Scarpone M, Kuebler D, Chambers A, et al. Isolation of clinically relevant concentrations of bone marrow mesenchymal stem cells without centrifugation 11 Medical and Health Sciences 1103 Clinical Sciences. *J Transl Med.* 2019;17(1):1-10. doi:10.1186/S12967-018-1750-X/FIGURES/2
 46. Osteo-Core-Plasty™ with Marrow Cellution™ | Aspire Medical Innovation.